

NON-DIAGNOSTIC AIDS-ASSOCIATED MALIGNANT NEOPLASMS

P Barnardt, MB ChB, Dip Oncol
Radiation Oncology, Tygerberg Hospital, W Cape

Acquired immunodeficiency syndrome (AIDS) malignancies are a well-recognised and potentially lethal consequence of the disease. Three malignancies have shown an increased incidence and qualify as AIDS-defining conditions when they occur in conjunction with HIV infection: Kaposi's sarcoma (KS), non-Hodgkin's lymphoma (NHL), including primary central nervous system lymphoma (PCNSL), and invasive cancer of the cervix. Data from the AIDS-Cancer Match Registry Study Group¹ demonstrate the relative increased risk for the development of the three current AIDS-defining cancers, but also suggest an increase in Hodgkin's disease (HD) and, to a lesser degree, anal carcinoma, testicular seminoma and lip cancer. Highly active antiretroviral therapy (HAART) has exerted an effect on the incidence of malignancies. Since its implementation the incidence of KS and NHL has declined substantially, but there has been no major change in the incidence of cervical cancer or Hodgkin's disease.² The most common source of morbidity and mortality from AIDS has been opportunistic infections (OIs). Since the improvement in survival of patients with HIV infection, due to better prevention, the treatment of infectious complications and HAART, there appears to have been an increase in the incidence of malignant tumours, in particular those non-diagnostic of AIDS.

Certain principles common to the treatment of HIV-infected patients with cancer apply to various malignant conditions. Treatment of such patients is complex and requires knowledge and understanding of both oncology and HIV infection.

Problems encountered while treating patients with malignancy include:

- Immunosuppression induced by chemotherapy can further compromise the immunocellular deficit of HIV-infected patients and might facilitate the onset of OIs and/or the evolution of the HIV infection itself.
- In patients with non-AIDS-defining malignancies, the CD4+ count is usually normal or slightly decreased at diagnosis, but may become severely depressed during and after treatment, resulting in a higher susceptibility to OIs.
- HIV-associated leukopenia, due to HIV-myelodysplasia or nucleoside analogue therapy, makes the administration of conventional dosages of chemotherapy difficult.
- Tolerance to chemotherapy in HIV-infected patients is generally poor and requires frequent dose reductions and/or delays in therapy.

The goals of cancer therapy, curative versus palliative, and the status of the underlying HIV infection must be evaluated in each individual case (Table I). Treatment should include therapy for opportunistic infections (OIs) and the underlying HIV.

HODGKIN'S DISEASE

HD is the most common non-AIDS-defining tumour. The relative risk for HD in HIV-infected patients is consistent from

TABLE I. GUIDE TO MANAGEMENT OF PATIENTS WITH NON-AIDS-DEFINING MALIGNANCIES

Immune system	Characteristics		Treatment
Intact	CD4+	> 200 cells/ μ l	Treat as if HIV negative
	OIs Survival	Absent Years	Avoid wide RT fields
Intermediate	CD4+	50 - 200 cells/ μ l	Poor tolerance to RT and CT
		Downward trend of CD4+	Restrict RT fields Avoid CT Treat OIs
Poor	CD4+	< 50 cells/ μ l	Palliation
	OIs Survival	Life-threatening Months	Pain Bleeding
			RT Short course Single fraction

OIs = opportunistic infections; CT = chemotherapy, RT = radiation therapy.

study to study.^{3,4} Although evidence suggests that HD might be associated with HIV-infected intravenous drug users, it does not appear to be restricted to this group only. The relationship between HD and HIV remains controversial and is not clearly understood. Despite these findings, it has been argued that both AIDS and HD affect patients in the 3rd and 4th decade of life, and that the association is merely coincidental. The relative risk for the development of HD in HIV-infected individuals varies from 7.9 to 8.5 in different studies.

However, when HD occurs, the presentation of disease in the HIV-infected patient differs from that in the HIV-negative individual. Investigators have noted that AIDS-HD is likely to

appear in younger patients, with a higher prevalence in males, and more advanced disease, stage III or IV (75 - 89%), at presentation. A higher percentage have B-symptoms (83%), which include night sweats, unexplained weight loss of more than 10%, pruritus and Pel Ebstein fever, and extranodal disease (63%), and patients are less likely to be cured (response rate 44 - 79%).⁵ AIDS-HD is characterised by the predominance of unfavourable subtypes, with mixed-cellularity or lymphocyte-depleted (53 - 63%) the most frequently diagnosed histological types. A high frequency (80 - 100%) of Epstein-Barr virus (EBV) has been identified in tissue from HIV-infected HD patients⁶ and might represent a factor involved in the pathogenesis of HIV-associated HD. Data from Carbone *et al.*⁷ display the bcl-6 syn-1 positive Reed-Sternberg phenotype HD cells, reflecting the post-germinal centre B-cell origin in the HIV-infected population. In contrast to the general population, HD Reed-Sternberg cells derive from germinal centre B-cells.

TREATMENT

The optimal therapy for AIDS-HD has not been defined. Considering that HD is an earlier manifestation of HIV infection than NHL (higher CD4+ cell count at presentation), the treatment approach for the two entities might be different (Fig. 1). Most patients present with advanced disease and have been treated with combination chemotherapy such as ABVD (doxorubicin, bleomycin, vinblastine and dacarbazine), but response rates remain dismal. Tolerance to chemotherapy has been poor and frequent dose reductions and/or delays in therapy are required. Response to therapy is far below that seen in the general population with HD, with a reported 1.5 years median overall survival. In the HIV-negative population more than 80% of patients with HD are alive at 10 years.

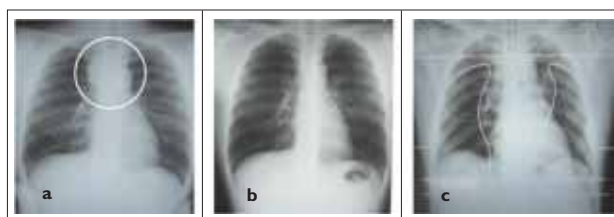


Fig. 1. Hodgkin's disease (a) at presentation, and (b) after 4 cycles of chemotherapy. (c) Simulator film for radiation therapy.

A study from the M D Anderson Cancer Center reported a 5-year overall survival rate of 54% with combination therapy (chemo- and radiotherapy) in AIDS-HD patients.⁸ In an attempt to improve response and survival rates, Zittoun *et al.*⁹ conducted a study with HAART-EBVP (epirubicin, bleomycin, vinblastine and prednisone) and *Pneumocystis carinii* pneumonia prophylaxis. Results of the trial showed an improved complete response rate of 74%. The 3-year disease-free survival and 3-year overall survival rates were 53% and 32% respectively, with the cause of death HD progression and OIs in 48% and 9% of patients. A prospective phase II study using a short-term Stanford V regimen with adjuvant radiotherapy showed this to be an active and feasible regimen in the setting of AIDS-HD, and concluded that the use of

concomitant HAART does not increase chemotherapy-related toxicity.¹⁰ Owing to the aggressive nature and advanced stages of AIDS-HD, more effective combined systemic anti-cancer and HAART therapy is required and should be used to improve the response and disease-free survival of AIDS-HD patients.

ANAL CARCINOMA

Several reports have suggested a slight increase in the incidence of squamous cell cancer of the anus associated with the HIV epidemic.¹¹ It is important to note that anal cancer was on the rise among homosexual men before the AIDS epidemic, owing to anogenital warts and sexual transmission of the human papillomavirus (HPV).¹² A high incidence of the human papilloma 16-type virus is associated with high-grade intra-epithelial neoplasia (AIN) and invasive cancer. It appears that HIV-induced immunosuppression allows reactivation of HPV, which leads to epithelial abnormalities. The incidence of AIN is significantly higher in homosexual men with HVP (61%) than in heterosexual men with HVP (4%). The incidence of anal cancer in HIV-positive men has been estimated at 70 per 100 000 persons per year.¹³ However, it is unclear whether the increase in anal cancer is directly linked to HIV alone.

TREATMENT

Anal cancer is very sensitive to combined-modality treatment (CMT) with chemoradiation therapy and is a highly curable cancer with a 65 - 75% long-term survival rate in the general population. Data suggest that HIV-infected patients with anal cancer should be managed with the same treatment as HIV-negative individuals.¹⁴

Two phase III randomised trials by the European Organization for Research and Treatment of Cancer (EORTC) and the Radiation Therapy Oncology Group (RTOG) showed the benefit of adding chemotherapy to radiation and led to the general acceptance of 5-fluorouracil/mitomycin C and radiation therapy as the standard of care.^{15,16} Radiation fields are designed to cover the main lesion, inguinal nodes, and low pelvic nodes. In patients with advanced HIV (CD4+ counts < 200/ μ l) mitomycin C should be withheld owing to the potential for severe myelosuppression and haemolytic-uraemic syndrome. There is evidence that HIV-infected patients who require therapy breaks (> 10 days) from chemoradiation due to severe skin reactions (Fig. 2) and dose reductions due to chemotherapy-related neutropenia have a higher incidence of local recurrence and a shorter survival.¹⁷ In several small trials 40 - 80% of patients remain disease free, with a median follow-up ranging from 8 to 38 months. Prophylaxis against OIs and HAART is highly recommended during this period of potential iatrogenic immunosuppression.

For patients with advanced disease whose life expectancy is measured in months, a palliative approach is appropriate. The main goal is to relieve pain and bleeding, allowing patients to maintain their dignity and quality of life. A short course of radiation is well tolerated and recommended. Great care should be taken not to irradiate bowel unnecessarily in a

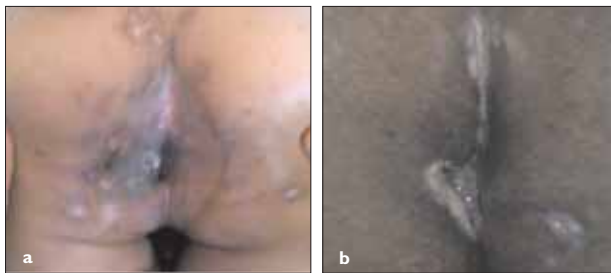


Fig. 2. Anal cancer: (a) skin reaction during radiation therapy, and (b) 6 weeks post radiation therapy.

population that might already be suffering from diseases such as chronic diarrhoea due to *Cryptosporidium* infections. As patients continue to live longer because of improved antiretroviral and prophylactic therapy, a rise in the incidence of invasive anal cancer is expected, which argues for better surveillance and screening for anal squamous intraepithelial lesions by anoscopy, cytology, and polymerase chain reaction (PCR) for HPV.

OTHER MALIGNANCIES IN THE HIV SETTING

HIV infection promotes immunosuppression which in turn fosters the development of malignancies. For most cancers, the higher prevalence is probably attributed to lifestyle factors among people with HIV. Malignancies may occur for reasons unrelated to immunosuppression, such as smoking and exposure to sexually transmitted HPV. As the AIDS epidemic advances, other tumours are increasingly seen in HIV-infected patients, including testicular cancer, lung cancer and basal cell carcinoma of the skin.

TESTICULAR CANCER

Recent data indicate that HIV-positive men have a significantly higher incidence of testicular cancer than the general population.¹⁸ An Italian series of HIV patients with testicular germ cell tumours (GCT) suggested that the association between testicular cancer and HIV is not directly related to immune function.¹⁹ The increase in seminoma was seen predominantly in homosexual males and white men. The majority of HIV-infected patients with GCT tolerate standard chemotherapy well and the majority obtain cure rates similar to those in the general population (Fig. 3). Treatment should include therapy for the underlying HIV and opportunistic infections (OIs).

LUNG CANCER

Epidemiological data do not support an increased incidence of lung cancer in the HIV-infected population. Tobacco smoking seems to be the major carcinogenic agent in both the HIV-infected and the general population. However, different features of lung cancer are observed in HIV-infected patients. The median age at presentation is younger, with adenocarcinoma being the predominant histological subtype. More than 70% of HIV patients present with advanced stages of disease, including 55% with metastatic disease at the time of

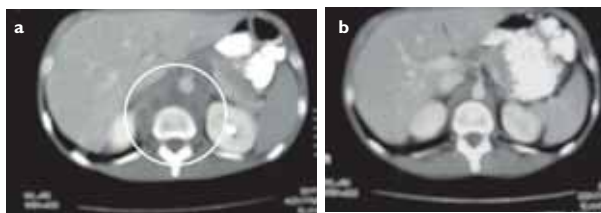


Fig. 3. Testicular cancer. Abdominal computed tomography scan with enlarged para-aortic lymph node mass, (a) pre- and (b) post chemotherapy, and (c) neoplasia of the right testis.

diagnosis.²⁰ Survival of HIV-positive patients with lung cancer remains poor, with a median survival of 6 months and only 10% of patients alive 1 year after diagnosis. If the HIV is under control, lung cancer should be managed with the same therapeutic strategies as in the general population.

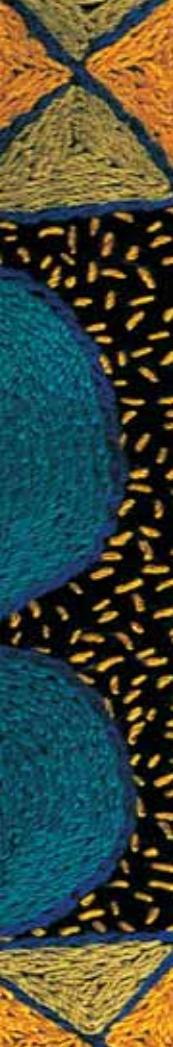
PAEDIATRIC MALIGNANCIES

A 2.5% incidence of cancer in children with AIDS was observed by the AIDS-Cancer Match Registry Study Group for children younger than 14 years. Children who develop AIDS appear to have an increased risk of developing malignancies of the same type as adults, particularly non-Hodgkin's lymphoma (NHL) and leiomyosarcoma.²¹ Burkitt's lymphoma was the most common lymphoma subtype and was diagnosed at a median of 14 months after the onset of AIDS. Kaposi's sarcoma was diagnosed within 2 years of the diagnosis of AIDS, and leiomyosarcoma tends to appear several years after the onset of AIDS.

CONCLUSION

Epidemiological reviews have failed to show a significant rise in the incidence of other malignancies in the HIV/AIDS setting.²² With the improvement in antiretroviral therapy and appropriate prophylaxis for OIs, life expectancy for patients with AIDS will continue to improve. Consideration should be given to the use of HAART and appropriate prophylaxis for OIs during treatment with radiation and/or chemotherapy for any of these diseases.

Data regarding the influence of HAART on the prognosis of malignancies remain difficult to interpret, with some studies claiming improved survival, e.g. for patients with NHL,²³ whereas others claim no influence. Therapeutic decisions should be based on the HIV patient's current location on the timeline of his or her disease. Patients with CD4+ counts above 200 cells/ μ l tolerate anti-neoplastic therapy as well as the general population but may suffer from long-term bone marrow and bowel toxicities. While HAART has improved morbidity and mortality in HIV-infected patients, malignant neoplasms and their successful treatment remain a challenge.



REFERENCES

1. Frisch M, Biggar RJ, Engels AE, *et al*, for the AIDS-Cancer Match Registry Study Group. Association of cancer with AIDS-related immunosuppression in adults. *JAMA* 2001; 85: 1736-1745.
2. International Collaboration on HIV and Cancer. Highly active antiretroviral therapy and incidence of cancer in human immunodeficiency virus-infected adults. *J Natl Cancer Inst* 2000; 92: 1823-1830.
3. Franceschi S, Dal Maso L, Arniani S, *et al*. Risk of cancer other than Kaposi's sarcoma and non-Hodgkin's lymphoma in persons with AIDS in Italy. *Br J Cancer* 1998; 78: 966-970.
4. Grulich A, Wan X, Law M, *et al*. Rates of non-AIDS defining cancers in people with AIDS. *J Acquir Immune Defic Synd Hum Retrovirol* 1997; 14: A18.
5. Errante D, Zaganel V, Vaccher E, *et al*. Hodgkin's disease with HIV infection and in the general population: comparison of clinicopathologic features and survival. *Ann Oncol* 1994; 2: 37-40.
6. Herndier BG, Sanchez HC, Chang KL, *et al*. High prevalence of Epstein-Barr virus in the Reed Sternberg cell of HIV-associated Hodgkin's disease. *Am J Pathol* 1993; 142: 1073-1079.
7. Carbone A, Gloghini A, Larocca LM, *et al*. Human immunodeficiency virus-associated Hodgkin's disease derives from post-germinal B cells. *Blood* 1999; 93: 2319-2326.
8. Tsimberidou AM, Sarris AH, Medeiros LJ, *et al*. Hodgkin's disease in patients with human immunodeficiency virus: frequency, presentation and clinical outcome. *Leuk Lymphoma* 2001; 41: 535-544.
9. Zittoun R, Eghbali H, Audebert A, *et al*. Association d'epirubicin, bleomycin, vinblastine et prednisonne (EBVP) avant radiotherapie dans le stades localises de la maladie de Hodgkin. *Bull Cancer* 1987; 74: 151-157.
10. Errante D, Gabarre J, Fasan M, *et al*. Feasibility of the integration of Stanford V chemotherapy regimen with highly active antiretroviral therapy (HAART) and G-CSF in patients with Hodgkin's disease and HIV infection (abstract). *Proc Am Soc Clin Oncol* 1999; 18: 37.
11. Melby M, Cote TR, Kessler L, *et al*. High incidence of anal cancer among AIDS patients. The AIDS/Cancer Working Group. *Lancet* 1994; 34: 636.
12. Levine AM. AIDS-related malignancies: The emerging epidemic (Review). *J Natl Cancer Inst* 1993; 85: 1382.
13. Biggar RJ, Rabkin CS. The epidemiology of AIDS-related neoplasms. *Hematol Oncol Clin North Am* 1996; 10: 997-1010.
14. Peddada A, Smith D, Rao A. Chemotherapy and low-dose radiotherapy in the treatment of HIV-infected patients with carcinoma of the anal canal. *Int Radiat Oncol Biol Phys* 1997; 37: 1101-1105.
15. Bartelink H, Roelofsens F, Eschwege F, *et al*. Concomitant radiotherapy and chemotherapy is superior to radiotherapy alone in the treatment of locally advanced anal cancer: results of a phase III randomized trial of the European Organization for Research and Treatment of Cancer Radiotherapy and Gastrointestinal Cooperative Groups. *J Clin Oncol* 1997; 15: 2040-2049.
16. Flam M, John M, Pajak TF, *et al*. Role of mitomycin in combination with fluorouracil and radiotherapy, and salvage chemoradiation in the definitive nonsurgical treatment of epidermoid carcinoma of the anal canal: results of a phase III randomized intergroup study. *J Clin Oncol* 1996; 14: 2527-2539.
17. Hollan JM, Swift PS. Tolerance of patients with human immunodeficiency virus and anal carcinoma to treatment with combined chemotherapy and radiation therapy. *Radiology* 1994; 193: 251-254.
18. Lyster DW, Bryant J, Thackeray R, *et al*. Non-AIDS defining malignancies in the Multicenter AIDS Cohort Study (MACS). 1984-1996. *J Acquir Immune Defic Synd Hum Retrovirol* 1998; 17(4): 13.
19. Bernardi D, Salvioni R, Vaccher E, *et al*. Testicular germ cell tumors and human immunodeficiency virus infection: a report of 26 cases. *J Clin Oncol* 1995; 13: 2705-2711.
20. Spina M, Sandri S, Serraino D, *et al*. Therapy of non-small lung cancers (NSCLC) in patients with HIV infection. *Ann Oncol* 1999; 10: 87-90.
21. Chadwick EG, Connor EJ, Hanson IC, *et al*. Tumors of smooth-muscle origin in HIV-infected children. *JAMA* 1990; 263: 3182-3184.
22. Rabkin CS. Epidemiology of AIDS-related malignancies (Review). *Curr Opin Oncol* 1994; 6: 492.
23. Ratner L, Redden D, Hamzeh F, *et al*. Chemotherapy for HIV-NHL in combination with HAART. *J Clin Oncol* 2001; 15: 2171-2178.